

Original study

Thyroglobulin in lymph node fine-needle aspiration biopsy washout fluid. A tertiary center experience

Laura Deacu¹, Dan Alexandru Niculescu^{*,1,2}, Andra Carageorgheopol³, Dana Terzea⁴, Cătălina Poiană^{1,2}

¹Department of Pituitary and Neuroendocrine Disorders, “C. I. Parhon” National Institute of Endocrinology, Bucharest, Romania; ²Department of Endocrinology, “Carol Davila” University of Medicine and Pharmacy, Bucharest, Romania; ³Research Laboratory, “C.I. Parhon” National Institute of Endocrinology, Bucharest, Romania; ⁴Department of Pathology, “C.I. Parhon” National Institute of Endocrinology, Bucharest, Romania.

Abstract

Papillary thyroid carcinoma (PTC) is the most common type of thyroid cancer. Most PTC secretes thyroglobulin, a useful marker in monitoring preoperative staging and postoperative progression; in addition to serum thyroglobulin, fine needle aspiration washout thyroglobulin (FNA-Tg) is also used. Our aim was to determine the cut-off value for FNA-Tg in our center and to describe major discrepancies between FNA-Tg, cytology and pathology results of the lymph nodes. Methods: We retrospectively retrieved from the electronic database of our endocrinology center all the FNA-Tg measurements between December 10, 2019 and September 2021. For each measurement we also retrieved the corresponding sex, FNAB results and the pathology reports. FNA-Tg was measured by ECLIA immunoelectro-chemiluminescent method. Results: There were 58 FNAB and FNA-Tg of suspect cervical lymph nodes in 40 patients. There were 17 cytologically benign lymph nodes of which 13 had low and 4 had high FNA-Tg; 3 non-diagnostic cytology results of which one had high FNA-Tg; 38 PTC metastases of which 6 had low and 32 had high FNA-Tg titers. The cut-off value of FNA-Tg in our center is 10 ng/ml, with a sensitivity of 86.6% (in those with pathology reports available after surgery). Conclusions: Washout TG is useful in suspicious lymph nodes and has added value to cytology in selected cases. The cut-off value of FNA-Tg in our center is 10 ng/ml, with a sensitivity of 86.6%. However, we must consider the possible false negative results that may occur in some histological types of PTC.

Keywords: washout thyroglobulin; papillary thyroid carcinoma; lymph nodes; fine-needle aspiration biopsy

Introduction

Papillary thyroid carcinoma (PTC) is the most common type of thyroid cancer [1]. In most cases it does not have an aggressive clinical behavior and has a very good long-term prognosis. However, in some cases,

central or lateral compartment lymph nodes (LNs) metastases may occur either at the time of diagnosis or post thyroidectomy [2-4]. Most PTC secretes thyroglobulin, a useful marker in monitoring preoperative staging and postoperative progression.

Therefore, in addition to serum thyroglobulin, thyroglobulin washout fluid from lymph node fine-needle aspiration biopsy (FNA-Tg) is also used [5]. Thyroglobulin washout has the advantage that it can provide preoperative information about lymph nodes metastases compared to serum thyroglobulin which can only be used postoperatively.

Received: October 2021; Accepted after review: December 2021; Published: December 2021.

*Corresponding author: Dan Alexandru Niculescu, “Carol Davila” University, Endocrinology, 34-36 Aviatorilor Blvd, Bucharest, 011863, Romania. Email: dan.niculescu@umfcd.ro



FNA-Tg also provides additional information to the cytological examination.

Although it is a widely used method, cut-off values for thyroglobulin washout have not yet been established in our center.

Our aim was to determine the cut-off value for FNA-Tg in our center and to describe major discrepancies between FNA-Tg, cytology and pathology results of the lymph nodes.

Methods

Patients

We retrospectively retrieved from the electronic database of our endocrinology

center all the FNA-Tg measurements between December 10, 2019 and September 2021. For each measurement we also retrieved the corresponding sex, ultrasound guided fine needle aspiration biopsy cytology (FNAB) results and the pathology reports.

There were 40 patients who underwent 58 fine needle aspirations with thyroglobulin washout of suspect cervical lymph nodes. Of these, 24 lymph nodes had complete pathology reports, while the other 34 lymph nodes had only cytology reports.

We divided the LNs according to the cytological examination (benign, malignant, non-diagnostic), and then the LNs were grouped into surgical removed and non-surgical removed (Figure 1).

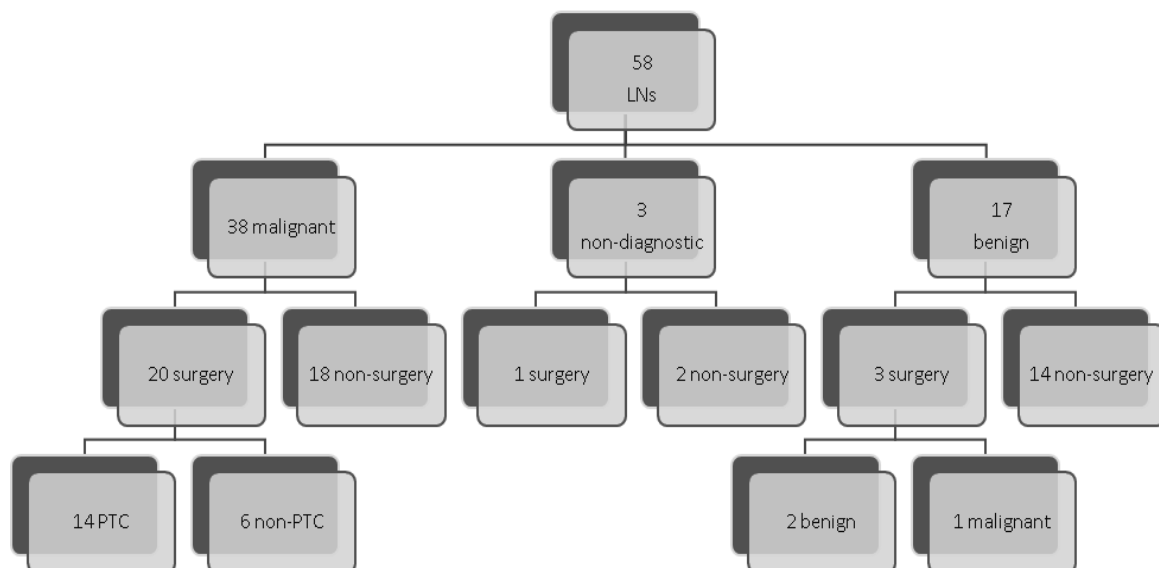


Fig. 1. Distribution of FNs according to the FNAB result

The pathological report of all 24 lymph nodes revealed: 15 PTC metastases (62.5%), 2 benign lymph nodes (8.33%), and 7 malignant lymph nodes (29.16%), but non-PTC.

Biochemistry

FNA-Tg was measured by ECLIA immunoelectro-chemiluminescent method. The limit of detection is 0.04 ng/ml and the functional sensitivity is 1 ng/ml.

All slides were stained, analyzed and interpreted by a pathologist from the “C. I. Parhon” National Institute of Endocrinology.

Statistics

Statistical analysis was carried out using the SigmaPlot 12.5 software (San Jose, CA) and the MedCalc 14.8.1 software (Ostend, Belgium).

Results

At the cytological examination were 17 *benign lymph nodes* (29.31%) from 14 patients, of which 3 patients were operated on. The first patient underwent surgery because, although he had a low FNA-Tg titer (0.04 ng/ml), he associated another lymph node with positive cytology and a high FNA-Tg titer. The second patient underwent surgery for the same reason as the first one, but it is worth mentioning a high titer of FNA-Tg in his case (197,752 ng/ml). The third patient underwent surgery due to the large discrepancy between the negative cytology and the high titer of FNA-Tg (5,888 ng/ml); the pathology report was positive for PTC only in the case of the third patient.

Of these 17 LNs with negative cytology for PTC, 4 showed high FNA-Tg titer with an average of 54,065 ng/ml. Two of these were previously mentioned, and the other two were not operated on, one of them having a cytological appearance of ectopic thyroid tissue.

The mean of all FNA-Tg measurements in patients with cytology negative for PTC was 12,721 ng/ml. Excluding the patient with

pathologic PTC, the mean FNA-Tg was 13,148 ng/ml.

Three of the 58 lymph nodes had a *non-diagnostic* cytological result (5.17%), 1 of them underwent surgery even in the context of a low FNA-TG titer, because the patient associated another adenopathy with malignant cytology, the pathological result pleading for poorly differentiated carcinoma.

The cytological examination revealed 38 lymph nodes with *malignant* appearance, of which 20 LNs (52.63%) were operated and the other 18 have no pathological report. Of the 20 operated LNs, 14 LNs (70%) had a pathological diagnosis of PTC. The other 6 lymph nodes were malignant, but non-PTC: 1 anaplastic thyroid carcinoma, 2 lymphomas and 3 carcinomatous metastases of unknown primary.

The lowest value of FNA-Tg was 0.14 ng/ml and the highest was 50,000 ng/ml with an average value of 28,168 ng/ml. Two (25%) of these FNA-Tg values were below 10 ng/ml (0.14; 3.33) and did not correlate with cytological and pathological results of PTC.

The FNA-Tg distribution depending on the cytology result is represented in Figure 2.

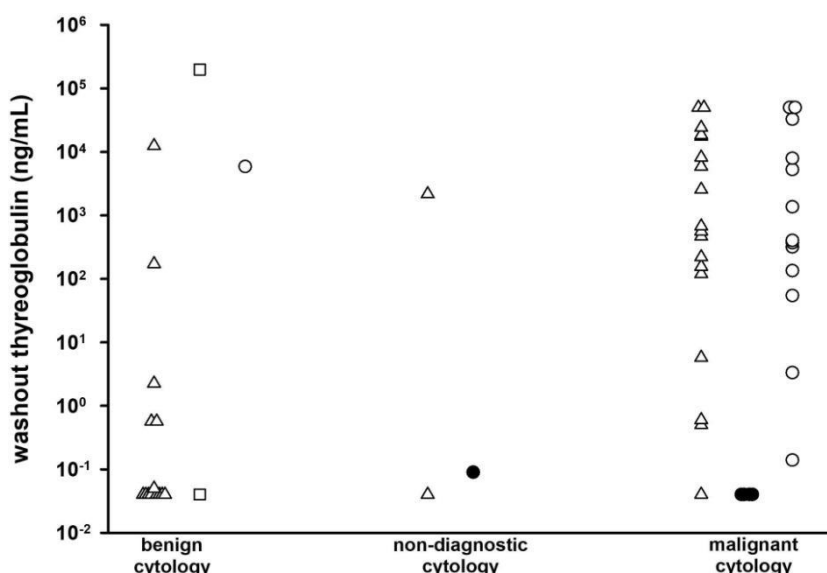


Fig. 2. Washout thyroglobulin in patients with benign, non-diagnostic or malignant cytology.



Empty triangles denote no pathology report available, empty squares denote benign pathology, empty circles denote papillary thyroid carcinoma and filled circles denote a non-PTC malignancy.

All cases where there was a discrepancy between FNA-Tg titer and cytology report are represented in Table I.

Table I. Cases with discrepancy between FNAB and FNA-Tg

Gender	Age (years)	FNA-Tg (ng/dl)	FNAB	Pathological Exam
F	54	12,451	benign	no
M	37	197,752	benign	benign
F	45	5,888	benign	diffuse sclerosing variant of PTC
F	47	172	ectopic thyroid tissue	no
F	39	0.14	malignant	tall cell variant of PTC
F	35	3.33	malignant	diffuse sclerosing variant of PTC

F- female; M-male; FNA-Tg - thyroglobulin washout fluid from lymph node fine-needle aspiration biopsy; FNAB - fine-needle aspiration biopsy; PTC - papillary thyroid carcinoma.

According to our study the cut-off value of FNA-Tg in PTC in our laboratory is 10 ng/ml. By using this cut-off value, our study showed that the washout Tg has a sensitivity of 86.66%.

Discussion

Washout Tg with ECLIA immunoassay has an analytical validation in our laboratory [6], but without a clinical cut-off. This cut-off value has a clinical importance, especially when it is accompanied by cytological examination of suspicious lymph nodes.

According to our study the cut-off value of washout Tg in PTC in our laboratory is 10 ng/ml. Compared to other studies, this cut-off value is even 10 times higher [7, 8].

There were two discordant cases with negative cytology for PTC, but with a high FNA-Tg titer (12,451 ng/ml and 172 ng/ml, respectively); unfortunately, the pathology report is not available, as the patients refused the surgery.

Another patient with PTC surgical removed, presented postsurgical a cervical formation in the left thyroid lodge, with a high FNA-Tg value (197,752 ng/ml), but with cytology suggestive for ectopic thyroid tissue; pathology examination confirmed that this formation was benign.

In another case with benign cytology and high FNA-Tg value (5,888 ng/ml), the lymph node was surgically removed because the patient presented another lymph node with cytology suggestive of PTC and increased Tg value; both LNs were PTC metastases.

Another 2 discordant cases are of some patients with PTC cytology, but with low FNA-Tg titer (0.14 ng/ml and 3.33 ng/ml, respectively). These two lymph nodes were surgically removed and the pathology reports were a tall cell variant of PTC and a diffuse sclerosing variant of PTC, respectively. Probably these false negative cases are due to a reduced capacity of the histological subtype of PTC to secrete thyroglobulin [9].

Although there were a few cases with discrepancy between the washout Tg and the cytological examination, most of the FNA-Tg values were consistent with both the cytological and pathological examination with a sensitivity of 86.66%, unlike other studies where sensitivity was 100% [10-12].

The main advantage was that all FNA-Tg were processed in the same laboratory, on the same machine.

Our study has several limitations. Firstly, we enrolled a small number of patients and we performed few FNA-Tg measurements. Secondly, not all FNA-Tg results were validated with pathological reports.



Conclusion

Washout TG is useful in suspicious lymph nodes as it added value to cytology in selected cases. The cut-off value of FNA-Tg in our center is 10 ng/ml, with a sensitivity of 86.6%. However, we must consider the possible false

negative results that may occur in some histological types of PTC.

Competing interests

The authors declare that they have no competing interests

References

1. Kim WB. A closer look at papillary thyroid carcinoma. *Endocrinol Metab (Seoul)*. 2015; 30(1):1-6. doi:10.3803/EnM.2015.30.1.1.
2. Wang LY, Ganly I. Nodal metastases in thyroid cancer: prognostic implications and management. *Future Oncol*. 2016; 12(7):981-994. doi:10.2217/fon.16.10
3. Wang LY, Palmer FL, Nixon IJ, et al. Lateral neck lymph node characteristics prognostic of outcome in patients with clinically evident n1b papillary thyroid cancer. *Ann Surg Oncol*. 2015; 22(11):3530-3536. doi:10.1245/s10434-015-4398-2.
4. Wang LY, Palmer FL, Nixon IJ, et al. Central lymph node characteristics predictive of outcome in patients with differentiated thyroid cancer. *Thyroid*. 2014; 24(12):1790-5. doi 10.1089/thy.2014.0256.
5. Konca Degertekin C, Yalcin MM, Cerit T, et al. Lymph node fine-needle aspiration washout thyroglobulin in papillary thyroid cancer: Diagnostic value and the effect of thyroglobulin antibodies. *Endocr Res*. 2016; 41(4):281-289. doi: 10.3109/07435800.2016.1141936.
6. Poalelungi C, Parvu L, Padure A, et al. Analytical validation of a thyroglobulin immunoassay in fine-needle aspirate washout of suspicious lymph nodes in patients with differentiated thyroid cancer. *Clinica Chimica Acta*. 2019; 493 (Supp 1):S317. doi:10.1016/j.cca.2019.03.690.
7. Moon JH, Kim YI, Lim JA, et al. Thyroglobulin in washout fluid from lymph node fine-needle aspiration biopsy in papillary thyroid cancer: large-scale validation of the cutoff value to determine malignancy and evaluation of discrepant results. *The J Clin Endocrinol Metab*. 2013; 98(3):1061-1068. doi: 10.1210/jc.2012-3291.
8. Jung JY, Shin JH, Han BK, Ko EY. Optimized cutoff value and indication for washout thyroglobulin level according to ultrasound findings in patients with well-differentiated thyroid cancer. *AJNR Am J Neuroradiol*. 2013; 34(12) 2349-235. doi: 10.3174/ajnr.A3687.
9. Casado CF, Bravo TA, Guerrero IM, Carrasco AR, García C, Villanueva Curto S. The value of thyroglobulin in washout of fine needle aspirate from 16 cervical lesions in patients with thyroid cancer. *Endocrinol Nutr*. 2013; 60(9):495-503. doi: 10.1016/j.endonu.2013.02.003.
10. Pacini F, Fugazzola L, Lippi F, et al. Detection of thyroglobulin in fine needle aspirates of nonthyroidal neck masses: a clue to the diagnosis of metastatic differentiated thyroid cancer. *J Clin Endocrinol Metab*. 1992; 74(6): 1401-1404. doi: 10.1210/jcem.74.6.1592886.
11. Mikosinski S, Pomorski L, Oszukowska L, et al. The diagnostic value of thyroglobulin concentration in fine-needle aspiration of the cervical lymph nodes in patients with differentiated thyroid cancer. *Endokrynol Pol*. 2006; 57(4):392-395.
12. Snozek CL, Chambers EP, Reading CC, et al. Serum thyroglobulin, high-resolution ultrasound, and lymph node thyroglobulin in diagnosis of differentiated thyroid carcinoma nodal metastases. *J Clin Endocrinol Metab*. 2007; 92(11):4278-4281. doi: 10.1210/jc.2007-1075.

