

Ocrelizumab-induced organizing pneumonia in multiple sclerosis: case report and literature review

Shaheryar Usman¹, Muhammad Cheema¹, Zoha Ghuman¹, Saleem Mustafa¹, Asma Iftikhar^{2,3,*}

¹Mather Hospital, Northwell Health, Port Jefferson, NY, USA. ²Division of Intensive Care Medicine and Pulmonary Medicine, Northwell Health, Port Jefferson, NY, USA. ³Donald and Barbara School of Medicine, Hofstra/Northwell, Hempstead, NY, USA.

*Correspondence: Asma Iftikhar, Division of Intensive Care Medicine and Pulmonary Medicine, Northwell Health, 60 N Country Rd, Port Jefferson 11777, NY, USA. Email: Aiftikhar@northwell.edu

How to cite this article: Usman S, Cheema M, Ghuman Z, Mustafa S, Iftikhar A. Ocrelizumab-induced organizing pneumonia in multiple sclerosis: case report and literature review. *Arch Clin Cases*. 2024;11(2):69-72. doi: 10.22551/2024.43.1102.10291

ABSTRACT

Patients with relapsing-remitting multiple sclerosis should be offered disease-modifying therapies as part of their management. Recommended options include integrin antagonist therapy including natalizumab as well as anti-CD20 monoclonal antibodies like, ocrelizumab, rituximab, ofatumumab, and ublituximab. These therapies reduce relapse rates and slow brain lesion accumulation. Disease-modifying therapies selection may depend on patient preferences, potential fetal harm, and specific drug risks, requiring continuous monitoring via tracking clinical relapses and new MRI brain lesions. Natalizumab carries a risk of progressive multifocal leukoencephalopathy, particularly in anti-JCV antibody-positive patients, necessitating regular monitoring. Ocrelizumab, rituximab, and ublituximab are associated with an increased risk of infections (especially respiratory and skin infections), infusion reactions, and hypogammaglobulinemia. Ocrelizumab additionally poses a heightened risk of immune-mediated colitis and breast cancer, and it is contraindicated for patients with active hepatitis B due to the risk of viral reactivation. Ublituximab has been noted to be linked to potential fetal harm. We report the case of a 42-year-old male with relapsing-remitting multiple sclerosis on ocrelizumab who developed persistent fever and shortness of breath, two weeks after his last ocrelizumab dose. Despite antibiotic treatment for suspected pneumonia, his symptoms persisted. A chest CT scan revealed multifocal ground-glass opacities suggestive of organizing pneumonia, likely secondary to ocrelizumab. The patient's condition improved with high-dose corticosteroids, underscoring the importance of vigilance for extremely rare ocrelizumab-associated pulmonary side effects and the need for prompt, appropriate intervention.

KEYWORDS: multiple sclerosis; drug-induced organizing pneumonia; ocrelizumab; ground glass opacities; steroids

INTRODUCTION

Recent efforts to develop new multiple sclerosis (MS) treatments have significantly assisted in improving patient's symptoms. Ocrelizumab, a recombinant humanized anti-CD20 monoclonal antibody, has shown considerable efficacy in treating relapsing-remitting multiple sclerosis (RRMS) [1]. However, its increased use has been associated with rare but severe side effects, including infections caused by herpes simplex virus, progressive multifocal leukoencephalopathy, and immune-induced colitis. This case report details a 42-year-old male MS patient who developed respiratory symptoms initially suspected to be secondary to bacterial pneumonia. Despite antibiotic treatment, the patient's condition did not improve, and CT chest imaging findings raised the suspicion of organizing pneumonia (OP) secondary to ocrelizumab. The patient was started on high dose steroids over months which helped resolve patient's pulmonary

disease. To date, only three similar cases have been reported in the literature [2-4]. This case underscores the critical need for healthcare providers to be vigilant about potential pulmonary side effects of MS treatment with ocrelizumab, particularly when symptoms mimic persistent respiratory infections and do not respond to antibiotics.

CASE PRESENTATION

A 42-year-old male with a history of multiple sclerosis was admitted to the hospital due to a fever of 38.8°C and shortness of breath for the last three days. The patient reported similar symptoms ten days ago and was admitted to another hospital. During the previous episode, the patient underwent a CT scan of the chest, which revealed multifocal multilobar confluent and ground glass acinar airspace opacities most advanced through the dependent portion of the right upper lobe and right middle lobe, suggestive of multifocal pneumonia (Figure 1). Patient was treated with the course of ceftriaxone and azithromycin. Post-antibiotic treatment, the patient's condition improved, leading to his discharge.

Received: May 2024; **Accepted after review:** June 2024;

Published: June 2024.



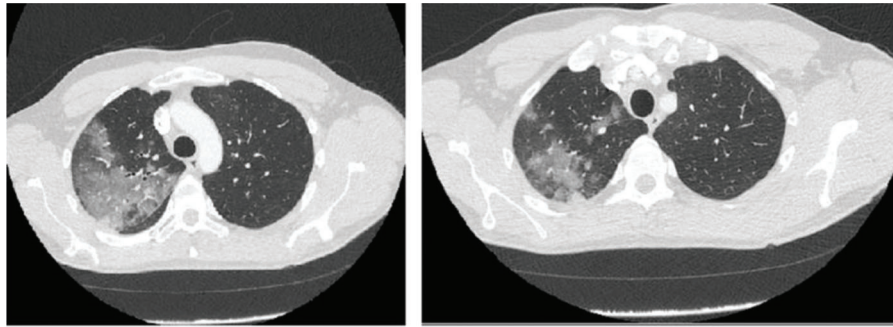


Fig. 1. CT scan of chest reveals multifocal multilobar confluent and ground glass acinar airspace opacities along with dependent portion of right upper lobe and right middle lobe, suggestive of multifocal pneumonia.

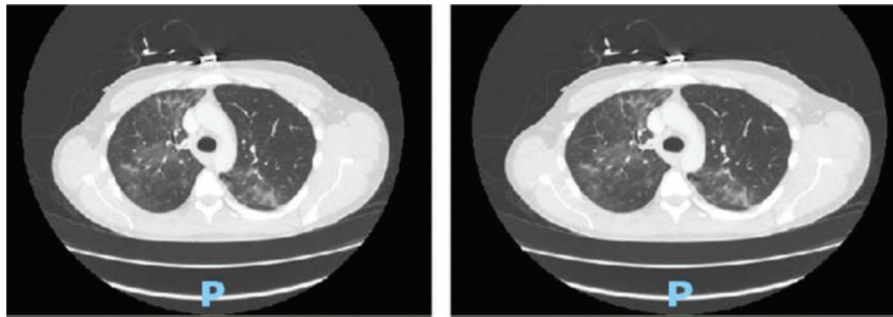


Fig. 2. CT scan of chest shows scattered ground glass and tree in bud opacities of all the lobes of both lungs suspicious for infectious vs. inflammatory etiology.

However, the relief was short-lived, as he began experiencing recurrent fevers, shortness of breath, and fatigue within a few days. The patient revealed that, in the recent past, he was started on ocrelizumab infusions 600 mg intravenous every six months, with the last dose administered two weeks prior to presentation. The patient denied high-risk behaviors, including travel, substance use, and smoking. He worked from home as an IT professional and lived alone. Vitals include a temperature of 38.3°C, blood pressure of 120/70 mmHg, heart rate of 98, and oxygen saturation of 94% on room air. On physical examination, the head was atraumatic, and pupils were equally reactive to light. Cardiac examination showed regular heart rate and rhythm without any murmurs. Chest examination revealed bilateral rales at the bases. Abdominal examination included a non-tender and soft abdomen. In contrast, musculoskeletal and neurological examination showed a full range of motion of all extremities. However, patient had bilateral lower extremity weakness due to multiple sclerosis and used a cane to ambulate. Lab work results showed white blood cell count of 7.40K/MicroL, hemoglobin level of 12.2 g/dl, platelet count of 404 K/MicroL, prothrombin time of 14.1 seconds, INR of 1.2, blood urea nitrogen level of 7mg/dl, and creatinine level of 0.59 mg/dl. Blood cultures, sputum culture (including acid-fast bacillus), HIV, and urine antigen tests for *Legionella*/*S. pneumoniae* were negative. Autoimmune tests were also negative, including antinuclear antibodies, antineutrophil cytoplasmic antibodies, and rheumatoid factor. CRP was 17.2 mg/L (normal level < 4mg/L). The CT scan of the chest showed scattered ground glass and tree-in-bud opacities of all five lobes of the lung, suspicious for pneumonia of infectious versus inflammatory etiology (Figure 2). The patient was treated empirically with IV vancomycin 1250mg twice a

day, cefepime 2g twice a day, and azithromycin 500mg once a day. Concurrently, IV methylprednisolone at 60mg daily was also administered. Within 48 hours, the fever had resolved. Upon discharge, the patient was prescribed oral prednisone 60mg daily oral for nine months, gradually tapering off over the next three months. Follow-up CT scans showed complete resolution of previously observed ground-glass opacities, with no suspicious nodules or consolidation (Figure 3).

■ DISCUSSION

Organizing pneumonia (OP) is a condition where fibrous tissue plugs form within the alveoli due to lung injury [5]. There are two types: secondary organizing pneumonia (SOP), caused by infections or medications, and cryptogenic organizing pneumonia (COP), which has an unknown cause. Triggers include infections, medications, exposure to harmful substances, malignancies, radiotherapy, and rheumatologic disorders. OP is theorized to result from a disruption in the alveolar-capillary barrier, leading to the leakage of plasma proteins into the alveoli [6,7].

Anti-CD20 monoclonal antibodies (mAbs) are used to treat multiple sclerosis (MS), including rituximab, ocrelizumab, ublituximab, and ofatumumab [8]. These drug-modifying agents (DMA) are usually continued indefinitely for stable RRMS patients unless there are intolerable side effects or safety concerns. However, older patients with no new relapses or MRI changes for a long time may consider stopping DMA. Ocrelizumab, rituximab, and ublituximab are associated with an increased risk of infections (especially respiratory and skin infections), infusion reactions, and hypogammaglobulinemia [9,10]. Ocrelizumab additionally poses a heightened risk of immune-mediated colitis and

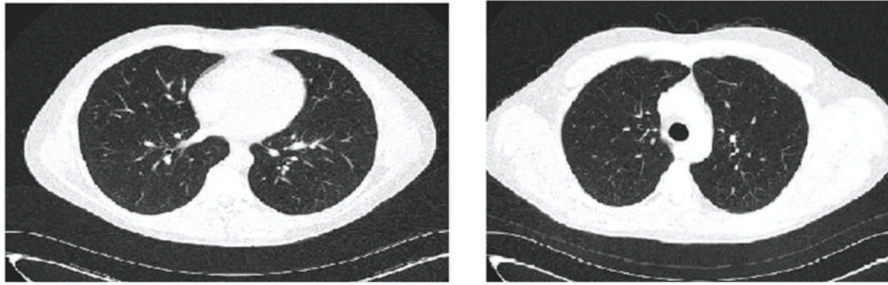


Fig. 3. CT scan showed complete resolution of previously observed ground glass opacities with no suspicious nodules or consolidation.

breast cancer and it is contraindicated for patients with active hepatitis B due to the risk of viral reactivation [11]. Ublituximab is also linked to potential fetal harm [12]. Of these four, rituximab and ocrelizumab have been reported to be associated with OP [13-15]. It is suggested that the complement system and cytokines like TNF- α , IL-6, and IL-8 may be involved in the pathophysiology of OP associated with rituximab use.

OP patients may experience symptoms similar to chronic pneumonia, such as dry cough, dyspnea, fever, anorexia, and malaise, often preceded by an upper respiratory tract infection [16]. Physical examination may reveal crackles/rales. Antibiotics may show temporary or no response. Blood tests are generally unremarkable except for elevated CRP levels. Specific inflammatory markers and antibodies such as ANA, RF, anticentromere, anti-SCL70, and myositis panels are recommended in cases linked to rheumatologic disorders.

Chest CT scans of OP patients typically show migrating consolidations predominantly in the lower lobes, featuring a subpleural and/or peribronchovascular distribution. Other signs include nodularities and ground-glass opacities with reverse halo signs [17,18]. The presence of honeycombing, pleural involvement, or significant lymphadenopathy warrants a reevaluation of the OP diagnosis and consideration of alternative diagnoses [19].

Diagnostic procedures like bronchoscopy can help to exclude other conditions such as infections and eosinophilic pneumonia. While transthoracic biopsies can be considered, especially for dense consolidations near the bronchial tree, surgical biopsies offer a definitive diagnosis, often revealing Masson bodies in the biopsy material.

The cornerstone of OP treatment is steroids, with a typical regimen starting with prednisone at 0.5-1 mg/kg/day for four weeks, followed by a tapering dose over six to twelve months based on patient response [6,20]. While clinical improvement is often rapid, radiological improvement may lag. Relapses upon reduction or discontinuation of steroid therapy necessitate a reevaluation of the diagnosis and potential underlying causes, with additional treatments like cyclophosphamide, azathioprine, mycophenolate, or rituximab considered for refractory cases. The prognosis for OP is generally favorable with steroid treatment, though some cases may progress to fibrosis resembling fibrotic nonspecific interstitial pneumonia.

To the best of our knowledge, there have been only three previously reported cases of OP associated with the use of ocrelizumab for durations of five-year, four-year, and three months respectively [2-4]. In all three instances, the patients presented with persistent fevers lasting over two weeks. Notably, temporary improvement under antibiotic therapy

was mentioned in only one of the cases. Diagnosis of OP in one case was concluded based on non-responsiveness to antibiotics and distinct findings on CT scans [3], prompting the start of steroid treatment, similar to our case. However, in the other two cases, patients underwent a transbronchial biopsy, which identified the presence of Masson bodies, and thus, the diagnosis of OP was confirmed [2,4]. Due to refractoriness to steroid therapy, azathioprine was subsequently added as an adjunct therapy in the second case [4]. Patients in all cases, including ours, positively responded to the treatment regime with alleviation of the symptoms and repeat chest CT scans showing resolution to the condition. After recovery, in one case, ocrelizumab therapy was not reinitiated [3], and the patient was monitored while off all DMA, like our case. In the other two cases, a further management plan was not mentioned. There is no consensual literature on how/what therapy to re-initiate once the patient recovers after OP in the setting of anti-CD 20 agents for MS, highlighting the need for further research in this matter.

As ocrelizumab is becoming more widely used to treat multiple sclerosis, healthcare providers must be aware of the potential link between the medication and organizing pneumonia. To ensure the safety of patients, we recommend closely monitoring those who are taking ocrelizumab for the development of any new respiratory symptoms and promptly investigating any possible lung involvement.

CONCLUSION

Ocrelizumab may cause drug-induced organizing pneumonia, similar to rituximab use in patients with multiple sclerosis. A failed antibiotic course, in combination with pertinent chest CT scan +/- lung biopsy finding, may aid in reaching an accurate diagnosis. Steroids, being the mainstay for treatment for organizing pneumonia, may not work for all patients, requiring additional immunosuppressants such as azathioprine and cyclophosphamide.

Conflict of Interest

None.

Informed Consent

Written informed consent was obtained from the patient for publication of this case report and accompanying images.

REFERENCES

- Hauser SL, Bar-Or A, Comi G, et al. Ocrelizumab versus Interferon Beta-1a in Relapsing Multiple Sclerosis. *N Engl J Med.* 2017 Jan 19; 376(3):221-234. PMID: 28002679. doi: 10.1056/NEJMoa1601277.

2. Rallabhandi SSH, Keelapandal Ganesh M, Paul V. Ocrelizumab Induced Organizing Pneumonia: A Case Report. In: *B54. CASE REPORTS IN ONCOLOGIC TREATMENT-RELATED LUNG DISEASE*. American Thoracic Society; 2024:A3863. doi: 10.1164/ajrccm-conference.2024.209.1_MeetingAbstracts.A3863.
3. Aysan N, Köybaşı G, Satıcı C, et al. Organizing pneumonia following ocrelizumab use in a patient with multiple sclerosis: A case report. *Tuberk Toraks*. 2023 Mar;71(1):107-111. PMID: 36912415; PMCID: PMC10795250. doi: 10.5578/tt.20239913.
4. Mattina G, Spina G, Gallo M, et al. A Second Case Report of Organizing Pneumonia following Ocrelizumab use in Patient with Multiple Sclerosis. *Medical and Research Publications*. <https://doi.org/10.5281/zenodo.10200370> [https://www.medicalandresearch.com/current_issue/1758, available at 9/7/2024]
5. Cordier JF. Cryptogenic organising pneumonia. *Eur Respir J*. 2006 Aug;28(2):422-446. PMID: 16880372. doi: 10.1183/09031936.06.00013505.
6. King TE Jr, Lee JS. Cryptogenic Organizing Pneumonia. *N Engl J Med*. 2022 Mar 17;386(11):1058-1069. PMID: 35294814. doi: 10.1056/NEJMra2116777.
7. American Thoracic Society; European Respiratory Society. American Thoracic Society/European Respiratory Society International Multidisciplinary Consensus Classification of the Idiopathic Interstitial Pneumonias. This joint statement of the American Thoracic Society (ATS), and the European Respiratory Society (ERS) was adopted by the ATS board of directors, June 2001 and by the ERS Executive Committee, June 2001. *Am J Respir Crit Care Med*. 2002 Jan 15;165(2):277-304. Erratum in: *Am J Respir Crit Care Med* 2002 Aug 1;166(3):426. PMID: 11790668. doi: 10.1164/ajrccm.165.2.ats01.
8. Gross RH, Corboy JR. Monitoring, Switching, and Stopping Multiple Sclerosis Disease-Modifying Therapies. *Continuum (Minneapolis)*. 2019 Jun;25(3):715-735. Erratum in: *Continuum (Minneapolis)*. 2019 Aug;25(4):1175. doi: 10.1212/01.CON.0000575052.49943.50. PMID: 31162313. doi: 10.1212/CON.0000000000000738.
9. Gloria Sánchez-Contreras. FDA Approves New Drug to Treat Multiple Sclerosis. Published February 20, 2018. [<https://www.fda.gov/news-events/comunicados-de-prensa/la-fda-aprueba-nuevo-medimento-para-tratar-la-esclerosis-multiple>, available at 7/7/2024]
10. Patel A, Sul J, Gordon ML, et al. Progressive Multifocal Leukoencephalopathy in a Patient With Progressive Multiple Sclerosis Treated With Ocrelizumab Monotherapy. *JAMA Neurol*. 2021 Jun 1;78(6):736-740. PMID: 33724354; PMCID: PMC7967248. doi: 10.1001/jamaneurol.2021.0627.
11. Ciardi MR, Iannetta M, Zingaropoli MA, et al. Reactivation of Hepatitis B Virus With Immune-Escape Mutations After Ocrelizumab Treatment for Multiple Sclerosis. *Open Forum Infect Dis*. 2018 Dec 26;6(1):ofy356. PMID: 30697576; PMCID: PMC6343960. doi: 10.1093/ofid/ofy356.
12. Lee A. Ublituximab: First Approval. *Drugs*. 2023 Apr;83(5):455-459. PMID: 36920653. doi: 10.1007/s40265-023-01854-z.
13. Mian M, Rass C, Hutarew G, et al. Extensive organizing pneumonia during chemo-immunotherapy containing rituximab and G-CSF in a patient with diffuse large B-cell lymphoma: case report and review of the literature. *Leuk Lymphoma*. 2006 Aug;47(8):1683-5. PMID: 16966286. doi: 10.1080/10428190600612586.
14. Biehn SE, Kirk D, Rivera MP, et al. Bronchiolitis obliterans with organizing pneumonia after rituximab therapy for non-Hodgkin's lymphoma. *Hematol Oncol*. 2006 Dec;24(4):234-7. PMID: 16948177. doi: 10.1002/hon.799.
15. Law S, Kwak Y, Felner K, et al. Organizing Pneumonia Associated With Rituximab Therapy for Treatment of Lymphoma. *Chest*. 2012; 142(4):483A. doi: 10.1378/chest.1390295.
16. Cherian S V, Patel D, Machnicki S, et al. Algorithmic Approach to the Diagnosis of Organizing Pneumonia. *Chest*. 2022;162(1):156-178. doi: 10.1016/j.chest.2021.12.659.
17. Ko JP, Girvin F, Moore W, Naidich DP. Approach to Peribronchovascular Disease on CT. *Semin Ultrasound CT MR*. 2019 Jun;40(3):187-199. PMID: 31200868; PMCID: PMC7126938. doi: 10.1053/j.sult.2018.12.002.
18. Biehn SE, Kirk D, Rivera MP, et al. Bronchiolitis obliterans with organizing pneumonia after rituximab therapy for non-Hodgkin's lymphoma. *Hematol Oncol*. 2006 Dec;24(4):234-237. PMID: 16948177. doi: 10.1002/hon.799.
19. Marquis KM, Hammer MM, Steinbrecher K, et al. CT Approach to Lung Injury. *Radiographics*. 2023 Jul;43(7):e220176. PMID: 37289644. doi: 10.1148/rg.220176.
20. Chong WH, Saha B, Ibrahim A, et al. Dyspnea in a 57-Year-Old Man With Recent Viral Illness. *Chest*. 2021 Jul;160(1):e19-e24. PMID: 34246383. doi: 10.1016/j.chest.2021.01.012.