

Retroperitoneal liposarcoma: unveiling diagnostic delays and multimodal treatment dilemmas

Vlad Ionuț Vlăsceanu ¹, Radu Petru Soroceanu ^{1,2,*}, Daniel Vasile Timofte ^{1,2},
Andi Gabriel Iordache ¹, Cristina Ciobanu Strobescu^{1,3}, Sergiu Timofte ^{1,2}

¹3rd Surgical Unit, "Sf. Spiridon" County Clinical Emergency Hospital, 700111 Iași, Romania. ²Department of Surgery, "Grigore T. Popa" University of Medicine and Pharmacy, 700115 Iași, Romania. ³Vascular Surgical Unit, "Sf. Spiridon" County Clinical Emergency Hospital, 700111 Iași, Romania.

*Correspondence: Radu Petru Soroceanu, Department of Surgery I, "Grigore T. Popa" University of Medicine and Pharmacy, 700115 Iași, Romania. Email: petru.soroceanu@umfiasi.ro

How to cite this article: Vlăsceanu VI, Soroceanu RP, Timofte DV, et al. Retroperitoneal liposarcoma: unveiling diagnostic delays and multimodal treatment dilemmas. Arch Clin Cases. 2023;10(4):187-190. doi: 10.22551/2023.41.1004.10272

ABSTRACT

Liposarcomas are a prevalent subtype of soft tissue sarcomas, constituting less than 1% of all malignancies. Originating in the adipose tissue, they can manifest in various locations and are categorized by the World Health Organization into several subtypes: well-differentiated liposarcomas, dedifferentiated liposarcomas, myxoid liposarcomas, pleomorphic liposarcomas and mixed-type liposarcomas. These tumors typically affect middle-aged and older individuals, and their incidence has been progressively increasing over the years. As liposarcomas advance they tend to encase blood vessels and major organs, particularly in the retroperitoneal area. Often asymptomatic initially, symptoms arise as the tumor reaches a considerable size, exerting pressure on adjacent tissues and organs. This report features a 54-year-old patient incidentally diagnosed with a substantial retroperitoneal tumor extending to the antero-lateral abdominal wall and inner thigh via the right inguinal ligament. The patient, with a previous three-year history of a right inguinal mass, sought acute care for a perianal abscess. The histological examination revealed morphological aspects consistent with a low-grade myxoid liposarcoma. While surgery remains the primary treatment for retroperitoneal liposarcomas, controversies exist regarding the role of radiotherapy and chemotherapy in improving survival rates. This case highlights the challenges in managing retroperitoneal tumors and underscores the importance of a personalized, multidisciplinary approach to optimize patient outcomes.

KEYWORDS: liposarcoma; retroperitoneal; surgery; low-grade; myxoid

INTRODUCTION

Among soft tissue sarcomas, liposarcomas stand out as one of the most prevalent subtypes, accounting for less than 1% of all malignancies [1,2]. Originating in adipose tissue, these tumors have the potential to develop in various locations [3,4]. The WHO categorizes liposarcomas into well-differentiated (WDL), dedifferentiated (DDL), myxoid (ML), pleomorphic (PL) and mixed-type (MTL) [5,6]. Each subtype reflects unique clinical characteristics, treatment responses, and fundamental biology. Enhanced comprehension of subtype-specific molecular pathology can guide clinical treatment choices and the exploration of new therapeutic approaches. Typically diagnosed in middle-aged and older individuals, the incidence of liposarcomas has exhibited an upward trend over the years [7]. As liposarcomas advance, they tend to encase blood vessels and major organs, particularly in the retroperitoneal area [8,9]. Often asymptomatic initially, symptoms manifest when the tumor reaches a considerable size, exerting pressure on adjacent

tissues and organs. Currently, there is no definitive evidence supporting the efficacy of either chemotherapy or radiotherapy in enhancing survival rates [10,11]. This case highlights the complex management of a rare retroperitoneal tumor, showcasing the challenges in achieving radical resection. Its unique characteristics, including an incidental diagnosis and extensive tumor size, offer valuable insights into comprehensive tumor management. Understanding liposarcomas is essential and requires healthcare professionals' awareness for early detection and intervention.

CASE PRESENTATION

A 54-year-old patient with no significant medical history presented at the Emergency Department reporting perianal pain and fever persisting for two days. Clinical examination revealed a 2x2 cm fluctuant area indicative of a perianal abscess. Additionally, an 8x10 cm painless, irreducible, solid, non-pulsatile mass was observed below Malgaigne's line, showing no local signs of inflammation. The patient's medical history revealed the appearance of the right inguinal mass three years ago, predating the COVID-19 pandemic. Consequently, the patient hesitated to seek timely medical

Received: October 2023; **Accepted after review:** November 2023;
Published: December 2023.



care for the right inguinal mass, leading to a significant delay in diagnosis and subsequent treatment. After addressing the acute pathology by incision and drainage of the perianal abscess, an abdominal ultrasound was conducted. The imaging revealed a large retroperitoneal mass extending to the abdominal wall and inner thigh, suggestive of a liposarcoma.

Subsequent contrast-enhanced computed tomography revealed a substantial retroperitoneal tumor measuring 117/131/203 mm (AP/T/CC). It displayed multilobulated contours without invasion signs, exerting pressure on nearby structures. The mass included the right inferior epigastric artery and right deep circumflex iliac. In contact with right iliopsoas muscle and pelvic iliac segment of right ureter, causing mild pelvic calyceal distension. The right common femoral, common iliac, and external iliac arteries were patent

without any signs of invasion. No suspicious osteolytic or osteosclerotic lesions indicative of secondary determinations were identified during the investigation (Figure 1).

As part of the surgical strategy to enhance intraoperative identification of the right ureter, a preoperative decision was made to place a J-J stent. A multidisciplinary surgical team, comprising general and vascular surgeons, performed a radical resection involving several procedures. These included a median laparotomy extended to the root of the thigh, inguinal ligament transection, radical tumor resection and a right-sided orchiectomy due to spermatic cord invasion (Figure 2). Reconstruction of the antero-lateral abdominal wall utilized a pre-peritoneal mesh, secured to Cooper's ligament, the pubic tubercle, the sheath of the rectus abdominis muscles, external oblique, internal oblique,

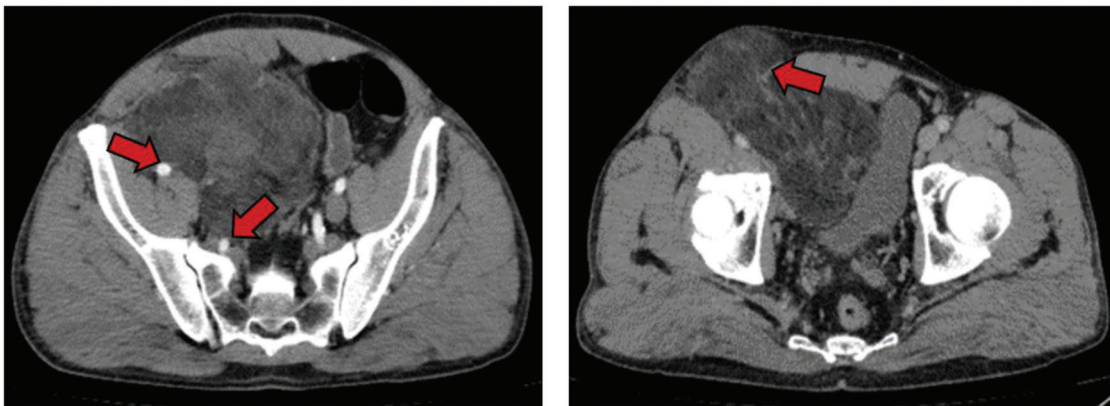


Fig. 1. Contrast-enhanced computed tomography sections depicting important details of the tumor: the contact with the right iliopsoas muscle and pelvic iliac segment of right ureter, common iliac, and external iliac arteries as pointed by the arrows on the left. The tumor extends through the inguinal ligament to the inner thigh as depicted by the arrow on the right.

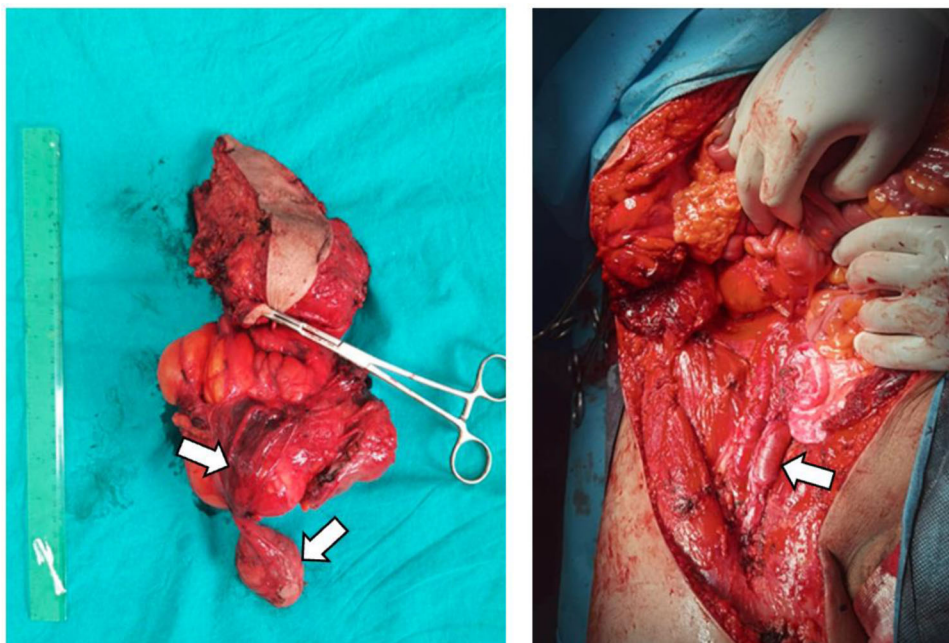


Fig. 2. The tumor specimen including the right gonad due to invasion of the spermatic chord as indicated by the arrows (left) and a view of the operative field after right inguinal ligament transection and dissection of the right femoral artery and vein as indicated by the arrow (right).

and transversus muscle near the anterior superior iliac spine. Preservation of the iliac and femoral vessels' integrity was ensured (Figure 3).

Post-surgery, the patient had a favorable recovery. However, lymphorrhagia, with a flow rate of approximately 200 ml/24h, developed five days post-operation. Attempts were made at lymphatic sclerotherapy using a 10% povidone-iodine solution instillation and the drainage was removed. The histopathological report confirmed a low-grade myxoid liposarcoma pT4N0 G2 L0V0Pn0.

Following discharge in overall good condition, the patient was referred to the regional oncology department, where he underwent six cycles of triple combination chemotherapy comprising doxorubicin, ifosfamide and mesna. Mesna, though not a cytostatic agent, was administered to prevent hemorrhagic cystitis, a common side effect of ifosfamide. The oncological treatment regimen was administered once every 21 days. The patient exhibited excellent tolerance to the chemotherapy and expressed satisfaction with the recovery process. Continuous follow-up care and surveillance are ongoing.

DISCUSSION

Retroperitoneal liposarcoma represents one of the most recognized histopathological forms of sarcoma, constituting approximately 20% of sarcomas in the adult population [13,16]. Prognostic factors influencing patients with retroperitoneal liposarcomas include mitotic rate, tumor size, negative resection margins, and histopathological type [14]. Larger tumor sizes often correlate with higher five-year rates of distant metastasis; for instance, tumors exceeding 20 cm may result in distant metastasis rates ranging from 55-60% over five years [15,16]. Abdominal liposarcomas typically exhibit a 10-year survival rate as low as 10% and are frequently associated with a high local recurrence rate, particularly in dedifferentiated liposarcomas.

Despite substantial progress in understanding the biology and developing new strategies for retroperitoneal sarcomas has been made, surgery remains the primary treatment modality [17]. Molecular therapies have not displayed significant efficacy, prompting ongoing studies focusing on unraveling the disease's molecular mechanisms. The role of radiotherapy, particularly preoperative radiotherapy, has been a subject of debate, with the STRASS trial demonstrating its effectiveness in specific scenarios. Retrospective studies suggest that preoperative radiotherapy improves the likelihood of achieving R0-R1 resections [19].

Careful planning within a multidisciplinary framework is imperative for surgical procedures, considering factors such as tumor stage and size, patient age, and comorbidities. Standardizing the surgical approach is crucial to maximize the chances of achieving complete R0 resections with negative microscopic margins [18]. In our case, the Multidisciplinary Team opted against preoperative neoadjuvant treatment, opting instead for surgery, pending reassessment after the histopathological report. This decision was influenced by the low mitotic index and the tumor's slow growth rate.

CONCLUSIONS

Managing retroperitoneal tumors remains a formidable challenge for surgical teams. In this unique case, the tumor's

distinct location necessitated a customized surgical strategy and intricate abdominal wall reconstruction. Key aspects vital to the successful radical resection of the tumor included precise vascular control and meticulous periaortofemoral dissection.

Several notable aspects characterize this case, including its incidental diagnosis, exacerbated by neglect amid the COVID-19 pandemic. Moreover, the tumor's size, extension along the iliac and femoral vessels, its projection through Fruchaud's musculopectineal defect, and its clinical manifestation in Scarpa's triangle add complexity to its management.

Conflict of interest

The authors declare that they have no competing interests.

Informed consent

Written informed consent was obtained from the patient for publication of this case report and accompanying images. A copy of the written consent is available for review by the Editor-in-Chief of this journal.

REFERENCES

1. Siegel RL, Miller KD, Fuchs HE, et al. Cancer Statistics, 2021. *CA Cancer J Clin*. 2021;71(1):7-33. Erratum in: *CA Cancer J Clin*. 2021 Jul;71(4):359. PMID: 33433946. doi: 10.3322/caac.21654.
2. Ray-Coquard I, Serre D, Reichardt P, et al. Options for treating different soft tissue sarcoma subtypes. *Future Oncol*. 2018;14(10):25-49. PMID: 29768052. doi: 10.2217/fon-2018-0076.
3. Thway K. Well-differentiated liposarcoma and dedifferentiated liposarcoma: An updated review. *Semin Diagn Pathol*. 2019;36(2):112-121. PMID: 30852045. doi: 10.1053/j.semdp.2019.02.006.
4. Mansfield SA, Pollock RE, Grignol VP. Surgery for Abdominal Well-Differentiated Liposarcoma. *Curr Treat Options Oncol*. 2018;19(1):1. PMID: 29335908. doi: 10.1007/s11864-018-0520-6.
5. Kallen ME, Hornick JL. The 2020 WHO Classification: What's New in Soft Tissue Tumor Pathology? *Am J Surg Pathol*. 2021;45(1):e1-e23. PMID: 32796172. doi: 10.1097/PAS.0000000000001552.
6. Improta L, Tzanis D, Bouhadiba T, et al. Overview of primary adult retroperitoneal tumours. *Eur J Surg Oncol*. 2020;46(9):1573-1579. PMID: 32600897. doi: 10.1016/j.ejso.2020.04.054.
7. Bock S, Hoffmann DG, Jiang Y, et al. Increasing Incidence of Liposarcoma: A Population-Based Study of National Surveillance Databases, 2001-2016. *Int J Environ Res Public Health*. 2020;17(8):2710. PMID: 32326423; PMCID: PMC7215751. doi: 10.3390/ijerph17082710.
8. Herrera-Almarino G, Cabrera LF, Londoño-Schimmer EE, et al. Giant retroperitoneal liposarcoma surgical management. *Ann R Coll Surg Engl*. 2022;104(2):54-56. PMID: 35100854. doi: 10.1308/rcsann.2021.0101.
9. Qiao Z, Zhan R, Pang Y, et al. Giant retroperitoneal dedifferentiated liposarcoma in an old man. *Asian J Surg*. 2021;44(8):1076-1078. PMID: 34045131. doi: 10.1016/j.asjsur.2021.05.007.
10. Wu YX, Liu JY, Liu JJ, et al. A retrospective, single-center cohort study on 65 patients with primary retroperitoneal liposarcoma. *Oncol Lett*. 2018;15(2):1799-1810. PMID: 29434876; PMCID: PMC5777090. doi: 10.3892/ol.2017.7533.
11. Lee ATJ, Thway K, Huang PH, et al. Clinical and Molecular Spectrum of Liposarcoma. *J Clin Oncol*. 2018;36(2):151-159. PMID: 29220294; PMCID: PMC5759315. doi: 10.1200/JCO.2017.74.9598.
12. Wei X, Qin Y, Ouyang S, et al. Challenging surgical treatment of giant retroperitoneal liposarcoma: A case report. *Oncol Lett*. 2022;24(3):314. PMID: 35949617; PMCID: PMC9353788. doi: 10.3892/ol.2022.13434.
13. Horowitz J, Singhal M, Marrero D, et al. A Multi-Modality Treatment of Retroperitoneal De-Differentiated Liposarcoma. *Am J Case Rep*.

- 2020;21:e919245. PMID: 32115569; PMCID: PMC7070895. doi: 10.12659/AJCR.919245.
14. WHO Classification of Tumors Editorial Board. *WHO classification of tumors of soft tissue and bone*. 5th ed. Lyon: IARC Press; 2020.
 15. McCallum OJ, Burke JJ 2nd, Childs AJ, et al. Retroperitoneal liposarcoma weighing over one hundred pounds with review of the literature. *Gynecol Oncol*. 2006;103(3):1152-4. PMID: 17007913. doi: 10.1016/j.ygyno.2006.08.005.
 16. Liao T, Du W, Li X, et al. Recurrent metastatic retroperitoneal dedifferentiated liposarcoma: a case report and literature review. *BMC Urol*. 2023;23(1):63. PMID: 37095466; PMCID: PMC10123999. doi: 10.1186/s12894-023-01252-3.
 17. Casadei L, de Faria FCC, Lopez-Aguilar A, et al. Targetable Pathways in the Treatment of Retroperitoneal Liposarcoma. *Cancers (Basel)*. 2022;14(6):1362. PMID: 35326514; PMCID: PMC8946646. doi: 10.3390/cancers14061362.
 18. Munoz P, Bretcha-Boix P, Artigas V, et al. Surgical Principles of Primary Retroperitoneal Sarcoma in the Era of Personalized Treatment: A Review of the Frontline Extended Surgery. *Cancers (Basel)*. 2022;14(17):4091. PMID: 36077627; PMCID: PMC9454716. doi: 10.3390/cancers14174091.
 19. Fevre CL, Waissi W, Chambrelant I, et al. A critical narrative review of radiotherapy for retroperitoneal soft tissue sarcoma. *Chin Clin Oncol*. 2020;9(6):79. PMID: 33412888. doi: 10.21037/cco-20-209.